

Original article

## Analyzing the efficacy of conservative versus surgical treatment of chronic mixed blepharitis via laser Doppler flowmetry and interferometry

Tatyana N. Safonova, Natalya P. Kintyukhina

Research Institute of Eye Diseases, Moscow, Russia

Received 2 September 2020, Revised 10 May 2021, Accepted 22 September 2021

© 2020, Russian Open Medical Journal

**Abstract:** *Objective* — To analyze and compare the efficacy of conservative vs. surgical treatment of chronic mixed blepharitis via laser Doppler flowmetry and interferometry.

*Materials and methods* — We enrolled 42 patients (the sample of 84 eyes) with chronic mixed blepharitis in the study. Laser Doppler flowmetry (LDF) was used to assess the microcirculation in the eyelid skin; interferometry was employed to evaluate the lipid layer of the tear film. Patients in the treatment group were treated by meibomian gland probing (MGP) and by artificial tears with a lipid component, introduced 4 times a day for 30 days. Subjects in the control group had their eyelid massaged in addition to administration of artificial tears. Treatment efficacy was monitored at 1 week, 1.5 months and 3 months.

*Results* — MGP demonstrated a statistically significant positive effect, which persisted for 3 months after the procedure: specifically, the restoration of the tear film stability by increasing the thickness of its lipid layer by 0.27-0.5  $\mu\text{m}$ . When comparing the interferoscopy results, an increase in the area of the lipid layer absence was detected in the control group. Analysis of LDF results showed a decrease in neurogenic and myogenic rhythms, as well as in the blood flow coefficient of variation in both groups. The lymph flow coefficient of variation remained stable in the treatment group, while it tended to decrease in the control group.

*Conclusion* — The obtained data analysis on the basis of objective instrumental assessment of the eyelid morphofunctional state by the methods of interferoscopy and LDF suggested that conducting MGP was more effective in chronic mixed blepharitis treatment, compared with performing an eyelid massage.

**Keywords:** blepharitis, meibomian gland probing, microcirculation, laser Doppler flowmetry.

Cite as Safonova TN, Kintyukhina NP. Analyzing the efficacy of conservative versus surgical treatment of chronic mixed blepharitis via laser Doppler flowmetry and interferometry. *Russian Open Medical Journal* 2022; 11: e0212.

Correspondence to Natalya P. Kintyukhina. Address: Research Institute of Eye Diseases 11 A, B, Rossolimo St., Moscow, 119021, Russia. Email: [natakint@yandex.ru](mailto:natakint@yandex.ru).

### Introduction

Mixed blepharitis accounts for 51.7% of all eye diseases. Furthermore, in 55% of cases, chronic blepharitis is accompanied by the meibomian gland dysfunction [1]. Normally functioning meibomian glands maintain the homeostasis of the ocular surface and prevent evaporative form of the dry eye syndrome. Clinically, chronic mixed blepharitis is a long-term disease with an intermittent course, frequent relapses, evident subjective symptoms with positive clinical dynamics, and the dry eye syndrome. Underestimating the degree of damage to the glands, along with a lack/inadequacy of regular therapy could lead to thickening, deformation and scarring of the eyelid edges, trichiasis and madarosis. An involvement of eyelid conjunctiva and cornea in the pathological process deteriorates the functional state of the eye even more and affects the patient psychoemotional profile [2, 3].

Currently, mixed chronic blepharitis is treated with drugs, concomitantly with an eyelid massage. However, long-term conservative therapy may not show any positive clinical dynamics, and patient's complaints could aggravate due to the disease

progression. Besides, an eyelid massage has a risk of causing subsequent meibomitis [4].

In 2015, S. Fermon was the first to demonstrate the efficacy of six-month meibomian gland probing (MGP) in chronic severe posterior blepharitis. However, in that study, along with a small sample size (16 patients), there was no objective assessment of the treatment efficacy via using instrumental methods for evaluating the lipid layer in the tear film, and eyelid skin [5]. There were no other similar studies among foreign publications.

The goal of blepharitis therapy include normalizing the lipid composition of the meibomian gland secretion, stabilizing the tear film, and increasing the drug accessibility to the meibomian glands [6].

The criteria for the efficacy of chronic mixed blepharitis treatment usually include the volume of tear production and the tear breakup time, along with the condition of the bulbar and palpebral conjunctiva, meibomian glands, their secretion, identified via biomicroscopy [7, 8].

The subjectivity of obtained results assessment may not reflect the true nature of the pathophysiological processes in the eyelids and meibomian glands.

Our previous studies substantiated the role of microcirculatory disorders in the development of chronic mixed blepharitis [9, 10, 11]. The parameters characterizing the perfusion and the amplitude-frequency spectrum of the blood-and-lymph flow in the eyelids were determined via laser Doppler flowmetry (LDF). The obtained results allowed an objective assessment of the inflammation degree. Hence, our earlier studies have become the prerequisite for using LDF as an objective criterion for determining the severity of eyelid lesions and the efficacy of therapeutic treatment of chronic mixed blepharitis.

LDF was widely used abroad because of the series of studies on the human cutaneous blood flow conducted in 1979-1984 by several research teams [12, 13]. LDF was later employed to assess the surficial blood flow in the eyelids after reconstructive surgeries in order to predict the viability of skin flaps and grafts, assess the state of periorbital tissues, benign and malignant lesions, and dermatochalasis [14, 15, 16]. There were no foreign studies of the blood flow and, especially, lymph flow in the eyelids in conditions of a chronic blepharitis.

Microcirculatory disorders are among the factors influencing the quantitative and qualitative composition of the meibomian gland secretion [17]. In this study, modified interferoscopy was used as an objective method for the comprehensive characterization of the condition of the lipid component in the tear film, and of meibomian glands in general, over time. A number of foreign authors used interferometry only for diagnosing the evaporative dry eye syndrome and the meibomian gland dysfunction [18, 19].

Along with clinical, functional and laboratory methods, the above-mentioned objective morphofunctional methods (interferoscopy and LDF) were used for the first time in our study to assess the conservative versus surgical treatment approaches to chronic blepharitis.

The study objective was to analyze and compare the efficacy of conservative versus surgical treatment of chronic mixed blepharitis based on laser Doppler flowmetry and interferometry data.

### Material and methods

The study included 42 patients (i.e., the sample of 84 eyes) with chronic mixed blepharitis without the signs of demodectic lesion of their eyelids (35 women and 7 men, 68.4±3.8 years old), randomly assigned into the treatment (20 patients, 40 eyes) and control groups (22 patients, 44 eyes). Both groups were identical in gender and age composition.

### Clinical and functional methods

All patients completed the Standard Patient Evaluation of Eye Dryness (SPEED) questionnaire and underwent clinical, functional, laboratory and instrumental eye examinations [20].

In the course of biomicroscopy, the integral indicator of eyelid inflammation (hyperemia and edema) and conjunctiva irritation (hyperemia, edema, conjunctival folds, conjunctival sac discharge) was calculated using a four-point scale, where 0 points corresponded to the absence of symptoms, 1 point to mild symptoms, 2 points to moderate symptoms, and 4 points to distinct symptoms [21].

The volume of tear production (Schirmer's test 1) [22], the tear breakup time (TBUT) [23], the number of actively functioning meibomian glands [24] were identified, and compression test was performed [25].

### Instrumental methods

The condition of the lipid layer in the tear film was evaluated via interferoscopy, based on analyzing the photographic image of the interference pattern of the color interference phenomenon. Digital images of the lipid layer were obtained using a photo-slit lamp with a special illuminator. In order to make the results of the study objective, *Lacrima* computer program (registration number 2010613451, Federal State Budgetary Scientific Institution 'Research Institute of Eye Diseases', Russia) was employed. This software analyses data on the thickness of the lipid layer and the area of investigated region, and determines the uniformity of the lipid distribution [26].

LDF was used to assess the eyelid skin microcirculation (peripheral blood and lymph flow analyzer *LAZMA MC* (LAZMA Scientific Production Enterprise LLC, Russia). Several parameters of the blood and lymph flow perfusion were measured during LDF. The coefficient of variation (CV) was calculated as the ratio of  $\sigma$  (mean perfusion fluctuation relative to the mean blood/lymph flow values) to M (mean perfusion of the blood/lymph flow within the recording time). The regulatory factor activity was computed as the ratio of A (the average of maximum amplitude values of oscillations in the corresponding frequency range) to M (myogenic rhythms of the blood flow). Neurogenic rhythms of the blood/lymph flow were measured as well [14].

### Laboratory tests

Microbiological testing of the conjunctival sac content and eyelid examinations for the presence of *Demodex gen.* were carried out [27].

### Treatment techniques

Patients in the treatment group were treated by MGP using a sterile microspatula (Titan Medical, Russia, No. ROSS RU.TSSH.K00713) with subsequent administration of artificial tears with a lipid component 4 times a day for 30 days [5]. Patients in the control group had their eyelid massaged (the total of 10 sessions) every other day in addition to administering artificial tears with a lipid component 4 times a day for 30 days [4]. Treatment efficacy was monitored at 1 week, 1.5 months and 3 months.

### Statistical data analysis

The data were statistically processed using Microsoft Office 2007, IBM SPSS Statistics v.22, and GraphPad Prism 6 for Windows. Data distribution was analyzed using the Shapiro-Wilk test. With a normal distribution of sample values, the mean value and its standard deviation were determined, and differences were assessed using Student's t-test, and paired samples t-test. When distribution differed from normal, the median and interquartile range were determined, and Mann-Whitney U test and Wilcoxon test were conducted. Differences between the values were considered statistically significant if the error probability was below 5% ( $p \leq 0.05$ ).

**Table 1. Dynamics of clinical and functional parameters during the patient follow-up**

Parameters	Patient group	Follow-up stages			
		Before	1 week after	1.5 months after	3 months after
Hyperemia of the eyelids, Me (25%; 75%), points	Treatment	4 (1;4)	2 (1;2)	1 (0;1)* p=0.038	1 (0;1)
	Control	4 (1;4)	3 (1;3)	2 (1;3)	2 (1;3)
Eyelid edema, Me (25%; 75%), points	Treatment	4 (2;4)	2 (1;2)	1 (0;1)* p=0.031	1 (0;1)
	Control	3 (1;3)	3 (1;3)	2 (1;3)	2 (1;3)
Schirmer's test 1, M ± SD, mm	Treatment	5.5±1.8	11.5±4.3	14.2±6.3* p=0.014	14.4±5.6
	Control	6.4±2.5	9.8±4.1	10.5±4.9	7.1±3.4
TBUT, M ± SD, s	Treatment	5.3±1.2	12.8±5.5* p=0.018	14.7±6.4* p=0.029	14.9±5.7
	Control	7.2±3.1	9.9±4.2	10.5±4.5	6.3±1.5
Compression test, Me (25%; 75%), points	Treatment	2 (1;2)	0 (0;1)* p=0.019	0 (0;1)	0 (0;1)
	Control	2 (0;2)	1 (0;1)	1 (0;2)	1 (0;2)
SPEED survey, Me (25%;75%), points	Treatment	18 (14;22)	8 (4;12)* p=0.025	6 (4;12)* p=0.042	6 (6;16)
	Control	16 (12;18)	12 (6;18)	10 (8;20)	18 (10;22)

TBUT, tear breakup time; SPEED, Standard Patient Evaluation of Eye Dryness survey; M±SD, mean and standard deviation; Me (25%; 75%), median and interquartile range (25<sup>th</sup>-75<sup>th</sup> percentile). \* – the data are statistically significantly different from the previous value.

**Table 2. Distribution of microcirculatory oscillation amplitudes at various follow-up stages**

Parameters	Patient group	Average values, M ± SD, %			
		Follow-up stages			
		Before	1 week after	1.5 months after	3 months after
Neurogenic blood flow rhythms	Treatment	2.3±0.4	6.2±2.8* p=0.021	11.5±4.5* p<0.001	9.1±3.2* p=0.026
	Control	1.9±0.2	2.5±0.6	5.2±1.2	4.8±1.7
Myogenic blood flow rhythms	Treatment	1.4±0.2	5.3±2.2* p=0.048	9.4±3.5* p=0.017	7.5±3.2* p=0.022
	Control	2.2±0.8	3.7±1.3	6.8±2.1	2.1±0.9
Neurogenic lymph flow rhythms	Treatment	3.5±1.2	9.6±3.5* p=0.041	12.1±5.6* p=0.012	10.5±4.3* p=0.035
	Control	4.7±1.5	4.5±1.6	4.3±1.7	2.8±0.4

M±SD, mean and standard deviation; \* – the data are statistically significantly different from the previous value.

## Results

The questionnaire scores, along with the results of clinical and functional patient examinations before the treatment and at different follow-up stages, are presented in *Table 1*.

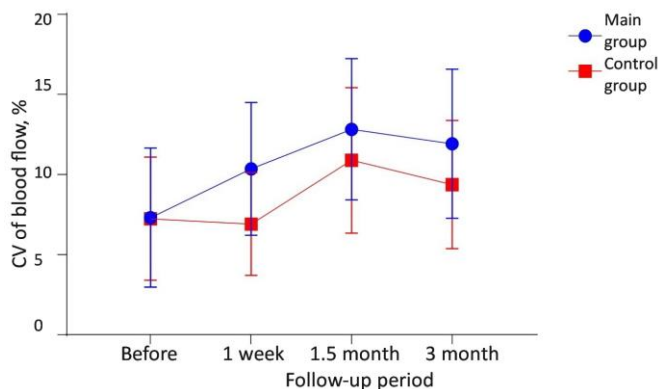
As demonstrated by the monitoring results at follow-up stages, the most pronounced clinical and functional results were obtained in the treatment group. Interferoscopy performed in both groups prior to the treatment, revealed that the areas without the lipid layer (47.4±6.8%, p=0.015 in the treatment group vs. 48.1±8.2%, p=0.023 in the control group), along with the areas with a thickness the lipid layer of 0.07-0.13 μm (45.3±9.4%, p=0.018 in the treatment group vs. 51.2±6.1%, p=0.044 in the control group), prevailed. Pretreatment LDF established the predominance of non-nutritive arterial hyperemia and ischemia in the eyelid skin, which was typical for moderate circulatory disorders (in a mixed congestive and ischemic form). Low activity of the lymph flow neurogenic rhythms was noted. The amplitude-vs.-frequency spectra of the blood and lymph flow microperfusion are presented in *Table 2*.

A week after the treatment, patients in both groups exhibited reduced SPEED scores and enlarged TBUT. The compression test in patients of the treatment group yielded a smaller score. Interferoscopy results revealed reduced area without the lipid layer in the tear film (39.5±8.2%, p=0.021 in the treatment group vs. 45.2±5.3%, p=0.035 in control subjects). An increase in the thickness of the lipid layer up to 4.8±1.7% (p<0.001) within the range of 0.27–0.5 μm was recorded only in treatment patients. LDF yielded higher coefficients of variation for both blood flow (*Figure 1*) and lymph flow (*Figure 2*) in the eyelids, accompanied by metabolism activation in the microcirculatory system, along with a

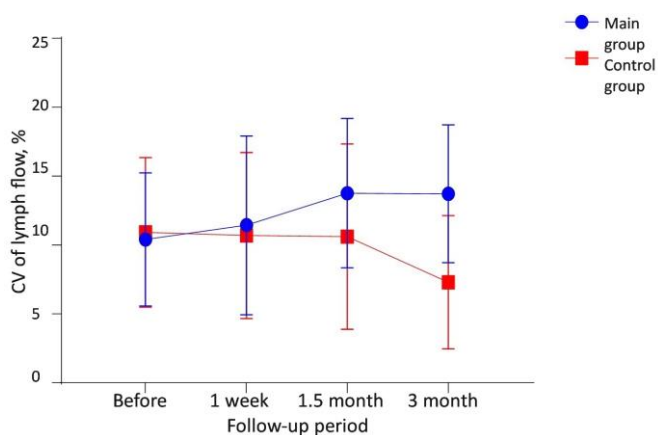
dominance of neurogenic rhythms in the lymph flow, exclusively in the treatment group.

One and a half months after MGP, questionnaire score, biomicroscopy, functional tests and instrumental examinations have demonstrated pronounced positive clinical responses. On the other hand, there were no changes in the clinical picture of patients in the control group. Interferoscopy revealed a decrease in the area without the lipid layer (35.1±4.6%, p=0.014 in the treatment group vs. 40.8±5.2%, p=0.028 in the control group), with a greater change observed in the treatment group. LDF of the blood flow in the study group revealed an increase in neurogenic (by 5.3%, p<0.001) and myogenic (by 4.1%, p=0.017) rhythms, and the former prevailed. At the same time, circulatory disorders were considered insignificant. In control group patients, values of the corresponding oscillations were lower. Furthermore, the activity of the lymph flow augmented in the treatment group: the coefficient of variation increased, with predominance of neurogenic rhythms.

At the 3-month follow-up stage, 62% (p=0.038) of patients in the control group showed an increase in the SPEED score. Interferoscopy in the treatment group exhibited an increase in the thickness of the lipid layer of the tear film up to 6.5±2.4% (p=0.011), within the range of 0.27-0.5 μm. On the contrary, in the control group, the areas without the lipid layer increased up to 50.4±7.1% (p=0.033), which implied destabilization of the tear film. LDF yielded a reduction in neurogenic and myogenic microcirculatory rhythms, and the blood flow coefficient of variation in both groups. The lymph flow coefficient of variation in the treatment group remained stable, whereas it tended to decline in the control group.



**Figure 1. Dynamics of the blood flow coefficient of variation at different follow-up stages. CV, coefficient of variation.**



**Figure 2. Dynamics of the lymph flow coefficient of variation at different follow-up stages. CV, coefficient of variation.**

### Discussion

The analysis of foreign and domestic publications disclosed that outpatient diagnostic methods of chronic blepharitis treatment impeded an objective assessment of the eyelid inflammation severity, as well as its persistence after the therapy [6, 7].

A number of foreign studies demonstrated an importance of interferometry of the lipid layer in the tear film to confirm the diagnosis of meibomian gland dysfunction and evaporative dry eye syndrome [18, 19]. However, the above method and was not used to assess the efficacy of conservative treatment of these conditions and to diagnose chronic blepharitis. The analysis of microcirculatory changes in the eyelid skin caused by blepharitis was not used for that purpose either. As a result, it was not possible to characterize comprehensively the morphofunctional state of the ocular surface [28].

In a few studies by foreign researchers, MGP was carried out solely in patients with obstructive dysfunction of the meibomian glands and ocular rosacea [6,29]. In such case, the criteria for assessing the efficacy of treatment were the parameters of such subjective methods as the ocular surface disease index, eyelid biomicroscopy, TBUT, compression test, Schirmer's test 1, and fluorescein eye staining [30, 31, 32]. The only time instrumental methods (meibometry, interferometry of the lipid layer of the tear film, and infrared meibography) were employed was the study by N. Nakayama et al., during which the methods were used to

demonstrate the pre- vs. post-MGP condition of meibomian glands in obstructive meibomian gland dysfunction [33].

In our study, the values of the indicators of the morphofunctional eyelid condition, obtained with LDF and interferoscopy, became decisive for the treatment efficacy assessment, as opposed to clinical and functional diagnostic methods. Chronic mixed blepharitis is known for destabilizing the quantitative and qualitative composition of the tear film [28]. The need for an objective assessment of the tear film changes, caused by this ailment, justified the use of interferoscopy, which had not previously been employed by foreign and domestic researchers for this purpose. In chronic blepharitis, the dynamics of such parameters, as the thickness of the lipid layer and the area without the lipid layer, serves an early indicator of both tear film destabilization and meibomian gland dysfunction.

In the course of conducting LDF, the main activity indicators of microcirculatory blood-and-lymph flow regulatory mechanisms, characterizing the extent of inflammation, were the coefficient of variation, along with neurogenic and myogenic rhythms, which supported the data of Kh.P. Takhchidi and I.A. Filatova [34, 35]. The coefficient of variation is an important objective parameter reflecting the overall state of microperfusion, an increase of which implies improvement. The influence of the sympathetic nervous system on arterioles determines the neurogenic tone. The myogenic tone is involved in the regulation of blood inflow into the nutritive capillary bed by means of precapillary sphincters [14]. Hence, the listed parameters were used as criteria for assessing the efficacy of chronic mixed blepharitis treatment.

The results of our study demonstrated the need for evidence in the form of using instrumental methods (interferoscopy and LDF) for assessing the therapy efficacy. The proven efficacy of minimally invasive surgical intervention, compared with eyelid massage, makes it possible to recommend MGP as a treatment option for chronic mixed blepharitis, especially considering the development of the resistance to conservative therapy.

### Conclusion

The analysis of the obtained data, conducted on the basis of an objective instrumental assessment of the morphofunctional eyelid state via interferometry and LDF, implied that performing MGP has exhibited a higher efficacy of treating chronic mixed blepharitis, compared with an eyelid massage.

### Conflict of interest

None declared.

### Ethical approval

All procedures performed in the study on human subjects complied with the ethical standards of the local ethics committee at the Federal State Budgetary Scientific Institution 'Research Institute of Eye Diseases', as well as 1964 Declaration of Helsinki (with later amendments) or equivalent ethical standards. This article does not mention any animal studies performed by any of the authors.

### References

1. Shokirova MM, Kopayeva VG. Evaluation of pathogenetic component of lacrimal substitutive therapy in the complex stage-by-stage treatment of posterior blepharitis, associated with demodectic lesions of the eyelid margins. *Fyodorov Journal of Ophthalmic Surgery* 2017;

- (1): 78-82. Russian. <https://doi.org/10.25276/0235-4160-2017-1-78-82>.
2. Auw-Hädrich C, Reinhard T. Blepharitis component of dry eye syndrome. *Ophthalmologie* 2018; 115(2): 93-99. German. <https://doi.org/10.1007/s00347-017-0606-8>.
  3. Safonova TN, Kintyukhina NP. Involutional blepharitis: Modern approaches to diagnostics and treatment. *Vestnik Oftalmologii* 2018; 134(1): 43-47. Russian. <https://doi.org/10.17116/oftalma2018134143-47>.
  4. Geerling G, Tauber J, Baudouin C, Goto E, Matsumoto Y, O'Brien T, et al. The international workshop on meibomian gland dysfunction: Report of the Subcommittee on Management and Treatment of Meibomian Gland Dysfunction. *Invest Ophthalmol Vis Sci* 2011; 52(4): 2050-2064. <https://doi.org/10.1167/iovs.10-6997g>.
  5. Fermon S, Zaga IH, Alvarez Melloni D. Intraductal meibomian gland probing for the treatment of blepharitis. *Arch Soc Esp Oftalmol* 2015; 90(2): 76-80. Spanish. <https://doi.org/10.1016/j.oftal.2014.04.014>.
  6. Syed ZA, Sutula FC. Dynamic intraductal meibomian probing: A modified approach to the treatment of obstructive meibomian gland dysfunction. *Ophthalmic Plast Reconstr Surg* 2017; 33(4): 307-309. <https://doi.org/10.1097/IOP.0000000000000876>.
  7. Auw-Hädrich C, Reinhard T. Treatment options for chronic blepharitis considering current evidence. *Ophthalmologie* 2016; 113(12): 1082-1085. German. <https://doi.org/10.1007/s00347-016-0382-x>.
  8. Arita R, Fukuoka S, Morishige N. New insights into the lipid layer of the tear film and meibomian glands. *Eye Contact Lens* 2017; 43(6): 335-339. <https://doi.org/10.1097/ICL.0000000000000369>.
  9. Safonova TN, Kintyukhina NP, Sidorov VV, Gladkova OV. Laser doppler flowmetry in assessing the effectiveness of treatment of chronic demodex blefaritis. *Russian Ophthalmological Journal* 2017; 10(2): 62-66. Russian. <https://doi.org/10.21516/2072-0076-2017-10-2-62-66>.
  10. Safonova TN, Kintyukhina NP, Sidorov VV, Gladkova OV, Reyn ES. Microcirculatory blood and lymph flow examination in eyelid skin by laser Doppler flowmetry. *Vestnik Oftalmologii* 2017; 133(3): 16-21. Russian. <https://doi.org/10.17116/oftalma2017133316-21>.
  11. Kintyukhina NP, Safonova TN, Gladkova OV. Using laser scanning confocal microscopy of the eyelid in the intraductal probing of the meibomian glands. *Sovremennye tehnologii v oftal'mologii* 2017; (4): 112-114. Russian. <https://elibrary.ru/item.asp?id=29933819>.
  12. Thomson FJ. Frequency multiplexer for ultrasonic Doppler blood flow signals. *Rev Sci Instrum* 1979; 50(7): 882-887. <https://doi.org/10.1063/1.1135944>.
  13. Oberg PA, Tenland T, Nilsson GE. Laser-Doppler flowmetry – a non-invasive and continuous method for blood flow evaluation in microvascular studies. *Acta Med Scand Suppl* 1984; 687: 17-24. <https://doi.org/10.1111/j.0954-6820.1984.tb08735.x>.
  14. Mannor GE, Wardell K, Wolfley DE, Nilsson GE. Laser Doppler perfusion imaging of eyelid skin. *Ophthalmic Plast Reconstr Surg* 1996; 12(3): 178-185. <https://doi.org/10.1097/00002341-199609000-00005>.
  15. Chao AH, Meyerson J, Pivoski SP, Kocak E. A review of devices used in the monitoring of microvascular free tissue transfers. *Expert Rev Med Devices* 2013; 10(5): 649-660. <https://doi.org/10.1586/17434440.2013.827527>.
  16. Khatib M, Jabir S, Fitzgerald O'Connor E, Philp B. A systematic review of the evolution of laser Doppler techniques in burn depth assessment. *Plast Surg Int* 2014; 2014: 621792. <https://doi.org/10.1155/2014/62179217>.
  17. Knop E, Knop N, Millar T, Obata H, Sullivan DA. The international workshop on meibomian gland dysfunction: Report of the subcommittee on anatomy, physiology, and pathophysiology of the meibomian gland. *Invest Ophthalmol Vis Sci* 2011; 52(4): 1938-1978. <https://doi.org/10.1167/iovs.10-6997c>.
  18. Matsumoto Y, Sato EA, Ibrahim OM, Dogru M, Tsubota K. The application of in vivo laser confocal microscopy to the diagnosis and evaluation of meibomian gland dysfunction. *Mol Vis* 2008; 14(9): 1263-1271. <http://www.ncbi.nlm.nih.gov/pmc/articles/pmc2447817>.
  19. Arita R, Fukuoka S, Morishige N. New insights into the morphology and function of meibomian glands. *Exp Eye Res* 2017; 163: 64-71. <https://doi.org/10.1016/j.exer.2017.06.010>.
  20. Ngo W, Situ P, Keir N, Korb D, Blackie C, Simpson T. Psychometric properties and validation of the Standard Patient Evaluation of Eye Dryness questionnaire. *Cornea* 2013; 32(9): 1204-1210. <https://doi.org/10.1097/ico.0b013e318294b0c0>.
  21. McCulley JP, Dougherty JM, Deneau DG. Classification of chronic blepharitis. *Ophthalmology* 1982; 89(10): 1173-1180. [https://doi.org/10.1016/s0161-6420\(82\)34669-2](https://doi.org/10.1016/s0161-6420(82)34669-2).
  22. Methodologies to diagnose and monitor dry eye disease: Report of the Diagnostic Methodology Subcommittee of the International Dry Eye Workshop (2007). *Ocul Surf* 2007; 5(2): 108-152. [https://doi.org/10.1016/s1542-0124\(12\)70083-6](https://doi.org/10.1016/s1542-0124(12)70083-6).
  23. Norn MS. Desiccation of the precorneal film. I. Corneal wetting-time. *Acta Ophthalmol (Copenh)* 1969; 47(4): 865-880. <https://doi.org/10.1111/j.1755-3768.1969.tb03711.x>.
  24. Hykin PG, Bron AJ. Age-related morphological changes in lid margin and meibomian gland anatomy. *Cornea* 1992; 11(4): 334-342. <https://doi.org/10.1097/00003226-199207000-00012>.
  25. Mathers WD, Shields WJ, Sachdev MS, Petroll WM, Jester JV. Meibomian gland dysfunction in chronic blepharitis. *Cornea* 1991; 10(4): 277-285. <https://doi.org/10.1097/00003226-199107000-00001>.
  26. Doane MG. An instrument for in vivo tear film interferometry. *Optom Vis Sci* 1989; 66(6): 383-388. <https://doi.org/10.1097/00006324-198906000-00008>.
  27. Huber-Spitz V, Baumgartner I, Böhler-Sommeregger K, Grabner G. Blepharitis – a diagnostic and therapeutic challenge. A report on 407 consecutive cases. *Graefes Arch Clin Exp Ophthalmol* 1991; 229(3): 224-227. <https://doi.org/10.1007/bf00167872>.
  28. Tomlinson A, Bron AJ, Korb DR, Amano S, Paugh JR, Pearce EI, et al. The international workshop on meibomian gland dysfunction: Report of the Diagnosis Subcommittee. *Invest Ophthalmol Vis Sci* 2011; 52(4): 2006-2049. <https://doi.org/10.1167/iovs.10-6997f>.
  29. Wladis EJ. Intraductal meibomian gland probing in the management of ocular rosacea. *Ophthalmic Plast Reconstr Surg* 2012; 28(6): 416-418. <https://doi.org/10.1097/iop.0b013e3182627ebc>.
  30. Ma X, Lu Y. Efficacy of intraductal meibomian gland probing on tear function in patients with obstructive meibomian gland dysfunction. *Cornea* 2016; 35(6): 725-730. <https://doi.org/10.1097/ico.0000000000000777>.
  31. Sik Sarman Z, Cucen B, Yuksel N, Cengiz A, Caglar Y. Effectiveness of intraductal meibomian gland probing for obstructive meibomian gland dysfunction. *Cornea* 2016; 35(6): 721-724. <https://doi.org/10.1097/ico.0000000000000820>.
  32. Kheirkhah A, Kobashi H, Girgis J, Jamali A, Ciolino JB, Hamrah P. A randomized, sham-controlled trial of intraductal meibomian gland probing with or without topical antibiotic/steroid for obstructive meibomian gland dysfunction. *Ocul Surf* 2020; 18(4): 852-856. <https://doi.org/10.1016/j.itos.2020.08.008>.
  33. Nakayama N, Kawashima M, Kaido M, Arita R, Tsubota K. Analysis of Meibum Before and After Intraductal meibomian gland probing in eyes with obstructive meibomian gland dysfunction. *Cornea* 2015; 34(10): 1206-1208. <https://doi.org/10.1097/ico.0000000000000558>.
  34. Takhchidi KP, Mitronina ML, Potapova LS, Sidorov VV. Investigation of microcirculation status of anterior segment of eyes by method of the laser doppler flowmetry in children with different refraction types. *Fyodorov Journal of Ophthalmic Surgery* 2011; (4): 49-53. Russian. <https://www.elibrary.ru/item.asp?id=18903089>.
  35. Filatova IA, Shemetov SA. Results of microcirculatory assessment after surgical treatment using polytetrafluoroethylene implants. *Annals of plastic, reconstructive and aesthetic surgery* 2018; 4: 135. Russian. <https://elibrary.ru/item.asp?id=37181879>.

---

*Authors:*

**Tatyana N. Safonova** – MD, PhD, Lead Researcher, Division of Lacrimal System Pathology, Research Institute of Eye Diseases, Moscow, Russia.  
<https://orcid.org/0000-0002-4601-0904>.

**Natalya P. Kintyukhina** – MD, PhD, Researcher, Division of Lacrimal System Pathology, Research Institute of Eye Diseases, Moscow, Russia.  
<https://orcid.org/0000-0002-2740-2793>.