ISSN 2304-3415, Russian Open Medical Journal
2025. Volume 14. Issue 1 (March). Article CID e0110
DOI: 10.15275/rusomj.2025.0110

Original article

Changes in the ocular surface condition during the transition to preservative-free hypotensive combination therapy in the long-term observation of patients with advanced stages of glaucoma

Dmitry A. Dorofeev [1], Aleksandr A. Vitkov [2], Elena V. Kirilik [1], Ksenia O. Lukyanova [1], Olga G. Pozdeeva [1,3]

[1] Chelyabinsk Public Clinical Hospital No. 2, Chelyabinsk, Russia
[2] Research Institute of Eye Diseases, Moscow, Russia
[3] South Ural State Medical University, Chelyabinsk, Russia

Received 21 January 2023, Revised 22 October 2024, Accepted 29 November 2024

© 2023, Russian Open Medical Journal

Abstract: *Overview* — Elevated intraocular pressure (IOP) is the main risk factor for the development and progression of primary open-angle glaucoma (POAG). Topical drugs, along with laser and surgical treatment options, are among the methods of IOP reduction. In most cases, topical hypotensive therapy is considered the first stage of glaucoma treatment. The transition to other treatment methods often occurs due to the ineffectiveness of long-term combination therapy. Most of the drugs used contain a preservative, which can negatively affect the condition of the ocular surface. The use of preservative-free fixed combinations (FC) can improve it with a similar hypotensive effect.
Objective — To study the condition of the ocular surface when replacing the preserved FC of brinzolamide 1%/timolol 0.5% with a preservative-free FC of tafluprost 0.0015%/timolol 0.5%.
Material and Methods — Group 1 (observation group) included patients with POAG in 20 (20.6%) eyes. Group 2 (control) included individuals without glaucoma who did not receive topical therapy in 77 (71%) eyes. The final study protocol included observational data at the time of inclusion in the study, as well as 1 month and 1 year after replacing the preserved FC of brinzolamide 1%/timolol 0.5% to the preservative-free FC of tafluprost 0.0015%/timolol 0.5%. All patients underwent a standard ophthalmological examination and assessment of structural and functional parameters, as well as examination of their ocular surface condition via the Norn test, Schirmer test, lissamine green vital staining, the Ocular Surface Disease Index (OSDI) questionnaire, and meniscometry 1 month and 1 year after the onset of the study.
Results — Results: No statistically significant changes in IOP were observed after switching from the preserved FC of brinzolamide 1%/timolol 0.5% to the preservative-free FC of tafluprost 0.0015%/timolol 0.5% (from 13.4±2.7 to 13.4±3.2 mmHg after 1 month and to 15.3±4.4 mmHg after 1 year). At all checkpoints, the condition of the ocular surface was similar between the groups ($p>0.05$) for all parameters, except for the OSDI questionnaire. After 1 month and 1 year of observation, no significant changes in the ocular surface were found in the groups using preservative-free Tapticom ® (Santen, Japan), except for the OSDI questionnaire after 1 year. The ratio of the tear meniscus depth and height based on OCT meniscometry data statistically significantly differed between the groups.
Conclusion — Long-term use of preservative-free Tapticom ® allowed effectively reducing the IOP to target values. This helped stabilizing structural and functional parameters without causing additional changes in the condition of the ocular surface. The transition from long-term treatment with preserved medications to preservative-free drug forms does not always lead to an improvement in the condition of the eyes. This may be due to a chronic process provoked by the preservative. Prescribing preservative-free therapy at the onset of treatment allows reducing the risk of developing dry eye syndrome and diminishing the subjective sensations in patients during long-term hypotensive therapy.

Keywords: glaucoma, preservative-free medications, hypotensive therapy, Norn test, Schirmer test, lissamine green vital staining, Ocular Surface Disease Index (OSDI), meniscometry.

Cite as Dorofeev DA, Vitkov AA, Kirilik EV, Lukyanova KO, Pozdeeva OG. Changes in the ocular surface condition during the transition to preservative-free hypotensive combination therapy in the long-term observation of patients with advanced stages of glaucoma. *Russian Open Medical Journal* 2025; 14: e0110.

Correspondence to Dmitry A. Dorofeev. Address: 200 Rossiyskaya St., Chelyabinsk 454090, Russia. Phone: +79124778927. E-mail: dimmm.83@gmail.com.

Introduction

The main modifiable risk factor for the development and progression of glaucoma is elevated intraocular pressure (IOP) [1, 2]. It is known that reducing IOP to target values slows down the progression of glaucoma [3-8]. According to the general strategy of glaucoma treatment, it should be started with monotherapy [9-16]. If it is ineffective, treatment should be intensified by adding antihypertensive drugs of other pharmacologic classes [17-19].

An increase in the number of instilled medications can lead to higher severity of local and systemic adverse events [20-22, 25]. This reduces patient compliance [23, 24]. In patients receiving topical antihypertensive therapy, ocular surface diseases occur in

60% of cases [26]. The severity of dry eye syndrome (DES) directly correlates with the number of prescribed medicines [27, 28]. Most national guidelines [17-19] and clinical recommendations [29] indicate prostaglandin analogs as first-line drugs. However, patients are often initially prescribed other pharmacologic classes, including fixed combinations (FC), most often containing benzalkonium chloride (BAC) as a preservative.

Currently, various forms of preservative-free topical antihypertensive agents are available. There are many studies comparing the efficacy and safety of preserved and preservative-free medications [20, 22, 30-34]. The possibility of switching from preserved glaucoma eye drops to preservative-free glaucoma therapy was also assessed and demonstrated the advantages of the latter [21, 30, 35-45].

An option for initial therapy may be the prescription of the FC of brinzolamide 1%/timolol 0.5%, containing a preservative. The regimen of use of these medications involves instillation twice a day. To improve the efficacy and tolerability of therapy, this drug can be replaced with FC with single instillation. Such a change in the antihypertensive regimen may improve both the patient's quality of life and adherence to treatment.

The goal of our study was to evaluate the ocular surface condition after replacing the preserved FC of brinzolamide 1%/timolol 0.5% with the preservative-free FC of tafluprost 0.0015%/timolol 0.5%.

Material and Methods

Study protocol

The study was conducted from February 2018 to February 2022 at the municipal health care institution (City Clinical Hospital No. 2), Outpatient Clinic No. 1, and City Glaucoma Office of Chelyabinsk. We analyzed the data from an analytical observational case-control study. In accordance with the inclusion and exclusion criteria, our study enrolled 97 patients (97 eyes) with and without glaucoma. In all cases, the diagnosis was established in accordance with the differential diagnosis of diseases and confirmed by specific research methods. The final study protocol included observational data at the time of inclusion in the study, as well as one month and one year after replacing the preserved FC of brinzolamide 1%/timolol 0.5% with preservative-free Tapticom ® (Santen, Japan). All patients underwent visual acuity test, iCare tonometry (Tiolat, Finland), standard automated perimetry (SAP) (Octopus-600, Haag-Streit diagnostics, Switzerland), optical coherence tomography (OCT) of the macular zone and optic disc, pachymetry and meniscometry using Revo NX (OPTOPOL Technology SA, Zawiercie, Poland).

Study of the ocular surface condition

At the onset of the study, as well as one month and one year after replacing the preserved FC of brinzolamide 1%/timolol 0.5% with a preservative with a preservative-free Tapticom ®, patients underwent a study of their ocular surface condition: Norn test, Schirmer test, lissamine green vital staining and a survey using the Ocular Surface Disease Index (OSDI) questionnaire.

Inclusion and exclusion criteria

Inclusion criteria: city of Chelyabinsk residents, patients with newly diagnosed primary open-angle glaucoma (POAG), 45-89 years of age (middle age, elderly, and old age sensu the 2012 classification by the World Health Organization, www.who.int/ru), and with clinical refraction in the range of ±3.0 D and astigmatism of ±1.5 D.

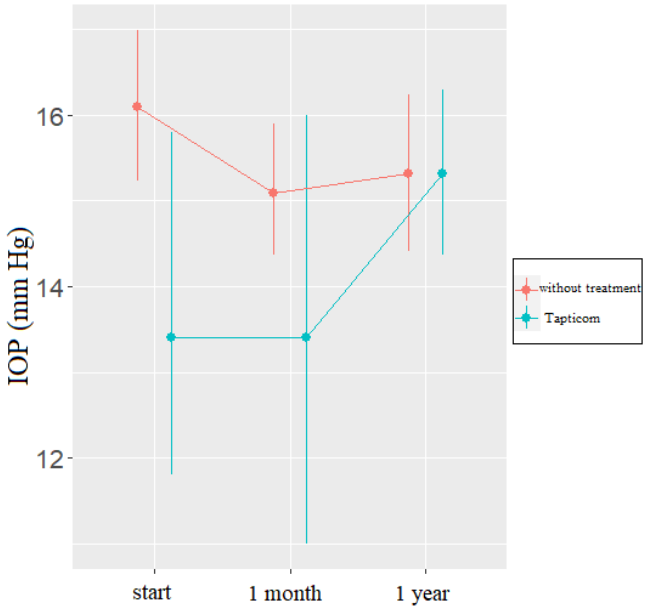

Figure 1. A graph of 95% confidence intervals of IOP using iCare tonometer at the start of treatment, after 1 month and 1 year of follow-up.

Table 1. Clinical and demographic characteristics of study groups

Parameter	*Group 1 (n=20)*	*Group 2 (n=77)*	*p-value*
Age, yrs	71.74±3.0; 72.2 (71.8; 74.0)	74.5±8.7; 74.3 (69.6; 80.6)	W=139; p=0.304
Number of women	16	66	X^2=0.0798; p=0.771
Anamnesis, yrs	2.3±2.2; 2.2 (0.2; 4.2)	–	–
BCVA	0.78±0.17; 0.8 (0.63; 0.9)	0.87±0.18; 1.0 (0.8; 1.0)	W=123.5; p=0.143
Se, D	-2.4±1.94; -2.0 (-3.5; -1.5)	-0.16±1.9; 0 (-1.25; 1.0)	W=73.5; p=0.021
CCT, mm	519±23; 514 (506; 526)	547±32; 550 (532; 566)	W=85; p=0.038
IOP_0, mm Hg	13.4±2.7; 13 (12; 13)	16.1±3.9; 16 (13; 18)	W=113; p=0.124
MD (dB)	-6.2±1.8; -6.1 (-6.9; -4.8)	-0.4±2.2; 0 (-1.9; 1.3)	W=11.5; p=0.0005
PSD (dB)	6.3±2.3; 7.0 (4.7; 8.4)	2.7±1.0; 2.5 (2.0; 3.2)	W=362; p=0.001
Optic disc, mm^2	2.4±0.4; 2.4 (2.2; 2.7)	2.2±0.4; 2.2 (1.9; 2.4)	W=242.5; p=0.337
RNFL, µm	83±12.5; 80 (73; 94)	97.5±10.5; 97 (90; 104)	W=77; p=0.025

BCVA, best corrected visual acuity; se, spherical equivalent; CCT, central corneal thickness; IOP_0, true level of intraocular pressure at the start of the study; MD, mean deviation of retinal sensitivity; PSD, pattern standard deviation of the MD of retinal sensitivity; RNFL, average thickness of the retinal nerve fiber layer in the peripapillary region; p-value, statistical significance of intergroup differences (Group 1 vs. Group 2).

© 2025, LLC Science and Innovations, Saratov, Russia

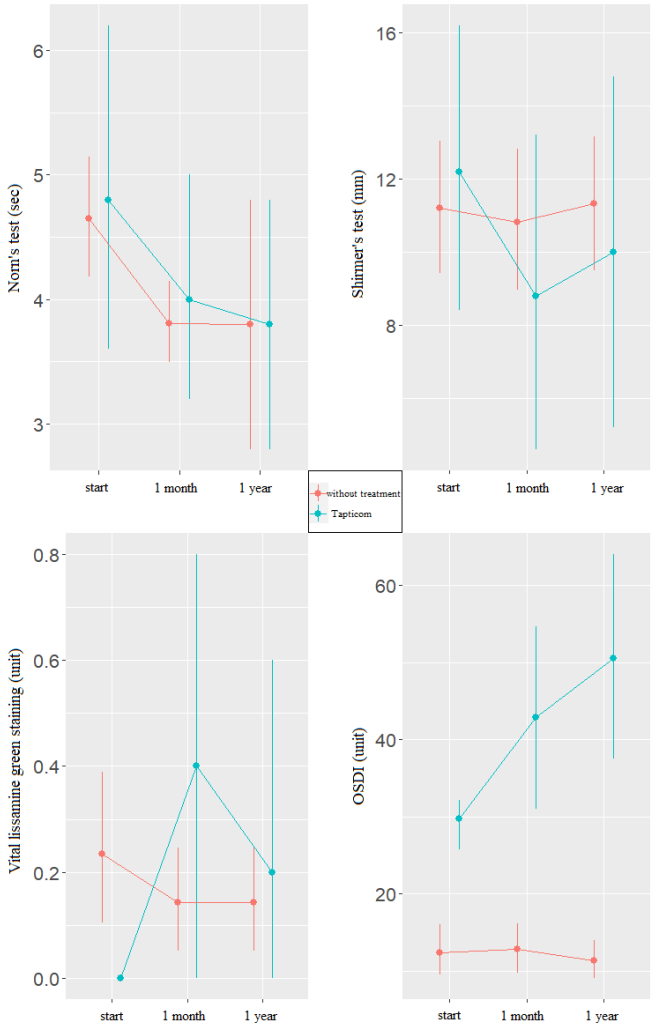

Figure 2. A graph of 95% confidence intervals for the Norn's test, Schirmer's test, vital lissamine green staining, OSDI questionnaire at the start of treatment, after 1 month and 1 year of follow-up.

Exclusion criteria: any other form of primary glaucoma, opacities of the optic media that prevent conducting standard automatic perimetry, other retinal diseases (any form of age-related macular degeneration, conditions after occlusions, diabetic retinopathy and its complications, specified in the guidelines for clinical trials, https://clinicaltrials.gov), history of surgical ophthalmologic procedure, eye injuries and diseases, diabetes mellitus, as well as other common diseases requiring hormone therapy.

Clinical and demographic characteristics

Among the examined patients, 82 (84%) were female and 15 (18%) were male. POAG was diagnosed in 20 (20.6%) eyes. Patient's age in Group 1 (observations) was 71.74±3.0 yrs; 72.2 (71.8; 74.0) yrs. Group 2 (control) encompassed individuals without glaucoma who did not receive topical treatment of 77 (71%) eyes, their age was 74.5±8.7 yrs; 74.3 (69.6; 80.6) yrs (W=139, p=0.304). The clinical and demographic characteristics of the groups are presented in *Table* 1. At the time of inclusion in the study, the groups differed statistically significantly in refraction, central corneal thickness, and structural and functional parameters.

Statistical data processing

The collected data were processed using R software environment for statistical computing and graphics (R Foundation for Statistical Computing, Vienna, Austria, https://www.R-project.org/). The presented parameters were tested for normality of distribution using the Shapiro-Wilk test, homogeneity of variance using the Bartlett's test, and are presented in the format M±σ; Me (Q25%; Q75%), where M is the mean, σ is the standard deviation of the mean, Me is the median, Q25% and Q75% are quartiles. The Wilcoxon signed-rank test was employed to compare two independent groups or repeated intragroup changes. The Pearson's chi-squared test was used to analyze differences in the empirical distribution of nominal data compared to the theoretical distribution for two-way contingency tables. The critical significance value for testing statistical hypotheses was assumed at <0.05.

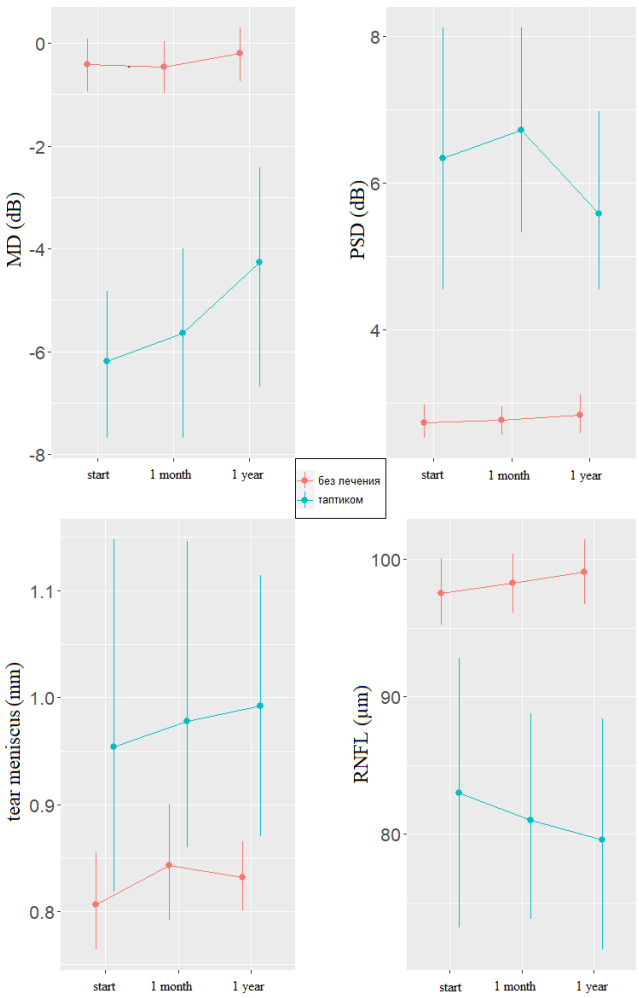

Figure 3. A graph of 95% confidence intervals of structural and functional data and OCT-meniscometry at the start of treatment, after 1 month and 1 year of follow-up.

Results

After switching from preserved FC of brinzolamide 1%/timolol 0.5% to the preservative-free FC Tapticom ®, we observed no statistically significant change in IOP (P_0 according to iCare altered from [13.4±2.7; 13(12;13)] mmHg to [13.4±3.2; 14(12;14)] mmHg 1 month after the onset of treatment and to [15.3±4.4; 15(12;17)] mmHg after 1 year (W=11, p=0.832; W=8.5, p=0.449) (*Figure* 1). Moreover, over the entire observation period, the IOP value was similar in both groups (W=113; p=0.124; W=198, p=0.922).

Changes in the ocular surface condition after 1 month and 1 year of observation according to the Norn test, Schirmer test, lissamine green vital staining, and the OSDI questionnaire are shown in *Figure* 2. At all checkpoints, the ocular surface condition was similar in the observation and control groups (p>0.05, *Table* 1) for all parameters, except for the OSDI questionnaire. This is probably due to a long history of using preserved forms of antihypertensive drugs: 2.3±2.2; 2.2(0.2; 4.2) years. After 1 month and 1 year of observation, we detected no statistically significant changes in the ocular surface according to the Norn test, Schirmer test, lissamine green vital staining, and the OSDI questionnaire (except for the OSDI questionnaire after 1 year of observation) in both groups using the preservative-free FC Tapticom ®. After 1 year of observation, according to OCT meniscometry, the ratio of the tear meniscus depth and height differed statistically significantly between the observation group and in the control group.

As expected, the structural and functional data differed between the control and observation groups (p<0.05, *Table* 1) for all indicators, while no statistically significant changes in the retinal sensitivity and average thickness of the retinal nerve fiber layer (RNFL) were detected after 1 month and 1 year of observation (*Figure* 3).

Discussion

The preservative-free FC Taptikom ® exhibited similar hypotensive effect to the preserved FC of brinzolamide 1%/timolol 0.5%.

After switching therapy, patients developed complaints typical of DES, which was probably due to both the patient's age or a more attention paid to the eyes. The ocular surface condition parameters in these patients did not change, which favors the second explanation. A statistically significant difference in the ratio of the tear meniscus depth and height between the observation group and the control group was revealed as well based on OCT meniscometry data. These data may indicate the onset of a pathological process after prescription of a preserved FC treatment. The transition to preservative-free therapy in this case did not affect the result, which should probably be interpreted as an indication for initial therapy with preservative-free medications. Hence, it can be concluded that for the prevention of DES, it is advisable to prescribe preservative-free forms of drugs already at the onset of treatment. Our assumptions are based on the data of a previous study, which examined the effect of the preservative-free drug tafluprost 0.0015% (Taflotan ®, Santen, Japan) on the ocular surface condition at the start of glaucoma therapy and did not detect any changes in the condition of the ocular surface during 1 year of observation [46].

Conclusion

Long-term use of the preservative-free FC Taptikom ® helps effectively reduce the IOC to target values. This allows stabilizing structural and functional parameters without causing additional changes in the ocular surface condition. Changing long-term preserved medication to preservative-free forms does not necessarily lead to an improvement in the condition of the eyes. This may be due to a chronic process triggered by the preservative. Prescription of preservative-free therapy at the onset of treatment will reduce the risk of developing DES and diminish the subjective sensations in patients during long-term hypotensive therapy.

Author contributions

The authors contributed equally to the preparation of the manuscript.

Funding

No external funding was provided for this study.

Conflict of interest

None declared by the authors.

Ethical approval

All procedures performed in this study involving human participants were in accordance with the ethical standards of the institutional research committee and with the 1964 Declaration of Helsinki and its later amendments.

References

1. Garway-Heath DF, Crabb DP, Bunce C, Lascaratos G, Amalfitano F, Anand N, et al. Latanoprost for open-angle glaucoma (UKGTS): A randomised, multicentre, placebo-controlled trial. *Lancet* 2015; 385(9975): 1295-1304. https://doi.org/10.1016/S0140-6736(14)62111-5.
2. Heijl A, Leske MC, Bengtsson B, Hyman L, Bengtsson B, Hussein M; Early Manifest Glaucoma Trial Group. Reduction of intraocular pressure and glaucoma progression: Results from the Early Manifest Glaucoma Trial. *Arch Ophthalmol* 2002; 120(10): 1268-1279. http://doi.org/10.1001/archopht.120.10.1268.
3. Stewart WC, Kolker AE, Sharpe ED, Day DG, Holmes KT, Leech JN, et al. Factors associated with long-term progression or stability in primary open-angle glaucoma. *Am J Ophthalmol* 2000; 130(3): 274-279. https://doi.org/10.1016/S0002-9394(00)00487-6.
4. Antonov AA, Vostrukhin SV, Volzhanin AV, Vitkov AA, Akimov AM, Asinovskova II. Influence of prostaglandin analogues on intraocular pressure fluctuations in body position change. *Russian Journal of Clinical Ophthalmology* 2022; 22(2): 103-107. Russian. http://doi.org/10.32364/2311-7729-2022-22-2-103-107.
5. Han YS, Ha A, Kim YK, Jeoung JW, Park KH. Normal-tension glaucoma management: A survey of glaucoma sub-specialists in Korea. *Korean J Ophthalmol* 2020; 34(6): 425-431. https://doi.org/10.3341/KJO.2020.0061.
6. Wilson R, Dueker DK, Walker AM, Pitts Crick R. Risk factors for rate of progression of glaucomatous visual field loss: A computer-based analysis. *Arch Ophthalmol* 1982; 100(5): 737-741. https://doi.org/10.1001/ARCHOPHT.1982.01030030741002.
7. Armaly MF, Krueger DE, Maunder L, Becker B, Hetherington J Jr, Kolker AE, et al. Biostatistical analysis of the collaborative glaucoma study. I. Summary report of the risk factors for glaucomatous visual-field defects. *Arch Ophthalmol* 1980; 98(12): 2163-2171. https://doi.org/10.1001/ARCHOPHT.1980.01020041015002.
8. Mansouri K, Tanna AP, De Moraes CG, Camp AS, Weinreb RN. Review of the measurement and management of 24-hour intraocular pressure

in patients with glaucoma. *Surv Ophthalmol* 2020; 65(2): 171-186. https://doi.org/10.1016/J.SURVOPHTHAL.2019.09.004.

9. Antonov AA, Kozlova IV, Vitkov AA. Maximum medical therapy for glaucoma – what is in our arsenal? National Journal glaucoma 2020; 19(2): 51-58. Russian. https://doi.org/10.25700/NJG.2020.02.06.
10. Avdeev RV, Alexandrov AS, Arapiev MU, Bakunina NA, Basinsky AS, Belaya DA, et al. Suspected glaucoma and early-stage glaucoma: Differential diagnostic criteria. *Russian Ophthalmological Journal* 2017; 10(4): 5-15. Russian. https://www.elibrary.ru/zvrlhn.
11. Avdeev RV, Alexandrov AS, Bakunina NA, Belaya DA, Brezhnev AYu, Volzhanin AV, et al. Comparison of treatment regimens for patients with primary open-angle glaucoma with signs of disease progression. Part 1. IOP levels. *National Journal glaucoma* 2018; 17(1): 14-29. Russian. https://doi.org/10.25700/NJG.2018.01.02.
12. Avdeev RV, Aleksandrov AS, Basinskiy AS, Blyum EA, Brezhnev AYu, Volkov EN, et al. Evaluation of clinical and instrumental data of eye examination in patients with primary open-angle glaucoma and macular degeneration. *Bashkortostan Medical Journal* 2014; 9(2): 24-28. Russian. https://www.elibrary.ru/szlbmr.
13. Bulakh IA, Zavadski PC, Lanin SN, Zvereva OG, Vitkov AA, Gaponko OV, et al. Clinical features of the progression of primary open-angle glaucoma in patients with a burdened family history. *National Journal Glaucoma* 2023; 22(2): 44-54. Russian. https://doi.org/10.53432/2078-4104-2023-22-2-44-54.
14. Abysheva LD, Avdeev RV, Alexandrov AS, Basinsky AS, Blyum EA, Brezhnev AYu, et al. Multicenter study of intraocular pressure level in patients with moderate and advanced primary open-angle glaucoma on treatment. *Ophthalmological Reports* 2015; 8(1): 43-60. Russian. https://doi.org/10.17816/OV2015143-60.
15. Kuroedov AV, Abysheva LD, Avdeev RV, Aleksandrov AS, Basinsky AS, Blyum EA, et al. Medico-economic multicenter study of local hypotensive therapy efficacy and cost for patients with primary open-angle glaucoma in CIS. *Ophthalmology Eastern Europe* 2015; (3): 35-51. Russian. https://www.elibrary.ru/uxqexx.
16. Ekgardt VF, Dorofeev DA, Shaimov TB, Deev RV. About the optic disc size. *Kazan Medical Journal* 2013; 94(6): 850-853. Russian. https://www.elibrary.ru/rshirh.
17. Weinreb RN, Leung CK, Crowston JG, Medeiros FA, Friedman DS, Wiggs JL, et al. Primary open-angle glaucoma. *Nat Rev Dis Primers* 2016; 2: 16067. https://doi.org/10.1038/nrdp.2016.67.
18. European Glaucoma Society Terminology and Guidelines for Glaucoma, 4th Edition – Chapter 2: Classification and terminologySupported by the EGS Foundation: Part 1: Foreword; Introduction; Glossary; Chapter 2 Classification and Terminology. *Br J Ophthalmol* 2017; 101(5): 73-127. https://doi.org/10.1136/bjophthalmol-2016-EGSguideline.002.
19. Egorov EA, Erichev VP, Eds. National Glaucoma Guidelines for Medical Practitioners. Moscow: GEOTAR-Media. 2019; 384 p. Russian. https://doi.org/10.33029/9704-5442-8-GLA-2020-1-384.
20. Dorofeev DA, Tur EV, Vizgalova LO, Tryapitsin ID, Ciganov AZ. The effect of preservative-free treatment of primary open-angle glaucoma on the state of ocular surface in combination therapy (intermediate results). *Russian Annals of Ophthalmology* 2019; 135(6): 52-59. Russian. https://doi.org/10.17116/oftalma201913506152.
21. Lovpache DN, Dorofeev DA. Pharmacoeconomic expediency of the use of preservative-free therapy in the treatment of primary open-angle glaucoma in patients with the dry eye syndrome (intermediate results). *RMJ. Clinical ophthalmology* 2017; (4): 195-200. Russian. https://doi.org/10.21689/2311-7729-2017-17-4-195-200.
22. Abysheva LD, Avdeev RV, Alexandrov AS, Arapiev MU, Bakunina NA, Baranova NA, et al. Influence of local hypotensive glaucoma therapy on the development and progression of dry eye syndrome. *RMJ. Clinical ophthalmology* 2017; (2): 74-82. Russian. https://doi.org/10.21689/2311-7729-2017-17-2-74-82.
23. Lovpache DN, Zavadski PCh, Zvereva OG, Kuroyedov AV, Dorofeev DA, Seleznev AV, et al. Compliance and persistence in patients with primary open-angle glaucoma from an ophthalmologist's perspective. *National Journal Glaucoma* 2020; 19(2): 11-21. Russian. https://doi.org/10.25700/NJG.2020.02.02.
24. Korneeva AV, Kuroyedov AV, Zavadski PCh, Gazizova IR, Lovpache DN, Onufriychuk ON, et al. Adherence to glaucoma hypotensive therapy: Patients' opinions on key factors of low compliance. Analytical multi-central study results. *National Journal Glaucoma* 2020; 19(3): 12-21. Russian. https://doi.org/10.25700/NJG.2020.03.02.
25. Erichev VP, Vitkov AA. Topical beta-blockers: Interactions and adverse events (Analytical review). In: XVIII Russian Nationwide School for Ophthalmology: Proceedings. Moscow, Russia. 2019: 37-45. Russian. https://www.elibrary.ru/ocrbto.
26. Prum BE, Rosenberg LF, Gedde SJ, Herndon LW, Lim MC, Williams RD, et al. Primary Open-Angle Glaucoma Preferred Practice Pattern® Guidelines. *Ophthalmology* 2016; 123(1): 41-111. https://doi.org/10.1016/j.ophtha.2015.10.053.
27. Baudouin C, Denoyer A, Desbenoit N, Hamm G, Grise A. In vitro and in vivo experimental studies on trabecular meshwork degeneration induced by benzalkonium chloride (An American Ophthalmological Society thesis). *Trans Am Ophthalmol Soc* 2012; 110: 40-63. https://pubmed.ncbi.nlm.nih.gov/23818734.
28. Chamard C, Larrieu S, Baudouin C, Bron A, Villain M, Daien V. Preservative-free versus preserved glaucoma eye drops and occurrence of glaucoma surgery. A retrospective study based on the French national health insurance information system, 2008-2016. *Acta Ophthalmol* 2020: 98(7): e876-e881. https://doi.org/10.1111/aos.14410.
29. Primary Open-Angle Glaucoma: Clinical Guidelines. 2020; 98 p. Russian. http://avo-portal.ru/documents/fkr/Klinicheskie_rekomendacii_POUG_2022.pdf.
30. Antonov AA, Kozlova IV, Vitkov AA. New opportunities in non-preservative glaucoma therapy. *Ophthalmology in Russia* 2021; 18(2): 260-265. Russian. https://doi.org/10.18008/1816-5095-2021-2-260-265.
31. Shedden A, Adamsons IA, Getson AJ, Laurence JK, Lines CR, Hewitt DJ, et al. Comparison of the efficacy and tolerability of preservative-free and preservative-containing formulations of the dorzolamide/timolol fixed combination (COSOPTTM) in patients with elevated intraocular pressure in a randomized clinical trial. *Graefes Arch Clin Exp Ophthalmol* 2010; 248(12): 1757-1764. https://doi.org/10.1007/s00417-010-1397-7.
32. Day DG, Walters TR, Schwartz GF, Mundorf TK, Liu C, Schiffman RM, et al. Bimatoprost 0.03% preservative-free ophthalmic solution versus bimatoprost 0.03% ophthalmic solution (Lumigan) for glaucoma or ocular hypertension: A 12-week, randomised, double-masked trial. *Br J Ophthalmol* 2013; 97(8): 989-993. https://doi.org/10.1136/bjophthalmol-2012-303040.
33. Subbot AM, Fisenko NV, Trufanov SV. Cytotoxicity of trusopt and dorzolan solo drugs to primary culture of human corneal endothelial cells. *Experimental and Clinical Pharmacology* 2020; 83(7): 27-31. Russian. https://doi.org/10.30906/0869-2092-2020-83-7-27-31.
34. Dorofeev DA, Kryzhanovskaya AV, Ciganov AZ. Effectiveness of antihypertensive conservative-free therapy with fixed combination of bimatoprost and timolol (intermediate results). *Vestn Oftalmol* 2020; 136(2): 73-80. Russian. https://doi.org/10.17116/oftalma202013602173.
35. Jaenen N, Baudouin C, Pouliquen P, Manni G, Figueiredo A, Zeyen T. Ocular symptoms and signs with preserved and preservative-free glaucoma medications. *Eur J Ophthalmol* 2007; 17(3): 341-349. https://doi.org/10.1177/112067210701700311.
36. Pisella PJ, Debbasch C, Hamard P, Creuzot-Garcher C, Rat P, Brignole F, et al. Conjunctival proinflammatory and proapoptotic effects of latanoprost and preserved and unpreserved timolol: An ex vivo and in

vivo study. *Investig Ophthalmol Vis Sci* 2004; 45(5): 1360-1368. https://doi.org/10.1167/iovs.03-1067.

37. Campagna P, Macri A, Rolando M, Calabria G. Chronic topical eye preservative-free beta-blocker therapy effect on the ocular surface in glaucomatous patients. *Acta Ophthalmol Scand Suppl* 1997; (224): 53. https://doi/10.1111/j.1600-0420.1997.tb00480.x.
38. Rouland JF, Traverso CE, Stalmans I, Fekih LE, Delval L, Renault D, et al. Efficacy and safety of preservative-free latanoprost eyedrops, compared with BAK-preserved latanoprost in patients with ocular hypertension or glaucoma. *Br J Ophthalmo* 2013; 97(2): 196-200. https://doi/10.1136/bjophthalmol-2012-302121.
39. Newman-Casey PA, Blachley T, Lee PP, Heisler M, Farris KB, Stein JD. Patterns of glaucoma medication adherence over four years of follow-up. *Ophthalmology* 2015; 122(10): 2010-2021. https://doi/10.1016/j.ophtha.2015.06.039.
40. Rossi GC, Tinelli C, Pasinetti GM, Milano G, Bianchi PE. Dry eye syndrome-related quality of life in glaucoma patients. *Eur J Ophthalmol* 2009; 19(4): 572-579. https://doi.org/10.1177/112067210901900409.
41. Katz G, Springs CL, Craven ER, Montecchi-Palmer M. Ocular surface disease in patients with glaucoma or ocular hypertension treated with either BAK-preserved latanoprost or BAK-free travoprost. *Clin Ophthalmol* 2010; 4: 1253-1261. https://doi.org/10.2147/OPTH.S14113.
42. Iester M, Telani S, Frezzotti P, Motolese I, Figus M, Fogagnolo P, et al. Ocular surface changes in glaucomatous patients treated with and without preservatives beta-blockers. *J Ocul Pharmacol Ther* 2014; 30(6): 476-481. http://doi.org/10.1089/jop.2013.0216.
43. Uusitalo H, Chen E, Pfeiffer N, Brignole-Baudouin F, Kaarniranta K, Leino M, et al. Switching from a preserved to a preservative-free prostaglandin preparation in topical glaucoma medication. *Acta Ophthalmol* 2010; 88(3): 329-336. https://doi.org/10.1111/j.1755-3768.2010.01907.x.
44. Egorov EA, Astakhov YuS, Erichev VP, Boiko AeV, Doga AV, Ryabtseva AA, et al. Evaluation of efficacy and safety of preservative-free 0.0015% tafluprost eye drops in patients with POAG and ocular hypertension. *Russian Journal of Clinical Ophthalmology* 2015; 15(1): 1. Russian. https://www.elibrary.ru/twipnh.
45. Dorofeev DA, Brezhnev AYu, Gazizova IR, Glasunova MA, Kirilik EV, Kuroedov AV, et al. Prerequisites to using preservative-free drugs in pharmacotherapy of glaucoma. *Ophthalmology in Russia* 2021; 18(3): 532-538. Russian. https://doi.org/10.18008/1816-5095-2021-3-532-538.
46. Dorofeev DA, Vitkov AA, Gorobets AV, Eskova MV, Efimova KA, Kanafin EV, et al. Effectiveness and safety of a hypotensive preservative-free drug in long-term therapy of glaucoma. *Russian Annals of Ophthalmology* 2022; 138(5): 66-72. Russian. https://doi.org/10.17116/oftalma202213805166.

Authors:
Dmitry A. Dorofeev – Ophthalmologist, Outpatient Clinic No.1, Chelyabinsk Public Clinical Hospital No.2, Chelyabinsk, Russia. https://orcid.org/0000-0003-3352-8170.
Aleksandr A. Vitkov – PhD, Researcher, Glaucoma Department, Research Institute of Eye Diseases, Moscow, Russia. https://orcid.org/0000-0001-7735-9650.
Elena V. Kirilik – Ophthalmologist, Outpatient Clinic No.1, Chelyabinsk Public Clinical Hospital No.2, Chelyabinsk, Russia. https://orcid.org/0000-0002-0189-9586.
Ksenia O. Lukyanova – Ophthalmologist, Outpatient Clinic No.1, Chelyabinsk Public Clinical Hospital No.2, Chelyabinsk, Russia. https://orcid.org/0000-0002-6781-3343.
Olga G. Pozdeeva – MD, DSc, Chief Physician, Outpatient Clinic No.1, Chelyabinsk Public Clinical Hospital No.2; Professor, Department of Ophthalmology, South Ural State Medical University, Chelyabinsk, Russia. https://orcid.org/0000-0003-0346-5332.

© 2025, LLC Science and Innovations, Saratov, Russia